



丹参酮 II A 通过调节 TGF- β 1/Smad2/MMPs 信号通路改善卵巢摘除大鼠关节软骨退行性改变*

郭琴, 郭苑莉, 廖凤儿, 陶莹[△]

广东药科大学附属第一医院/第一临床医学院 妇产科 (广州 510080)

【摘要】目的 探讨丹参酮 II A (tanshinone II A, Tan) 对卵巢切除 (绝经后雌激素缺乏模型) 大鼠骨关节退行性变的缓解作用及其机制。**方法** 将 8 周龄 SD 雌性大鼠随机分为 5 组 (每组 10 只): 假手术组 (Sham), 卵巢切除组 (OVX) 及低、中和高剂量 Tan 组。双侧卵巢切除术 8 周后, 分别给予大鼠 5、10 和 20 mg/kg Tan 治疗 28 d。通过 X 射线、解剖学观察、HE 染色和甲苯胺蓝染色组织学观察评估大鼠关节软骨情况。免疫组织化学检测软骨组织中转化生长因子 β 1 (transforming growth factor β 1, TGF- β 1)、磷酸化的 Smad2 (phosphorylated-smad2, p-Smad2)、II 型胶原 (type II collagen, C II)、基质金属蛋白酶 9 (matrix metalloproteinase 9, MMP-9) 和 MMP-13 的表达水平。**结果** X 射线、解剖学观察和组织学检测结果显示, OVX 组大鼠膝关节表现为关节间隙狭窄、骨赘形成、软骨侵蚀甚至局部软骨出现裂隙、软骨表面甲苯胺蓝染色变淡, 软骨细胞排列紊乱、潮线不清甚至中断, Kellgren-Lawrence 分级评分、Pelletier 分级评分、Mankin 评分和 OARSI 评分均较 Sham 组增高 ($P < 0.01$); Tan 可剂量依赖性改善 OVX 导致的上述膝关节退行性变, 提高 Kellgren-Lawrence 分级评分、Pelletier 分级评分、Mankin 评分和 OARSI 评分。免疫组化检测显示, 相对于 OVX 组, Tan 组软骨组织中 TGF- β 1、p-Smad2、C II 表达增高 ($P < 0.01$), MMP-9 和 MMP-13 表达降低 ($P < 0.01$), 且呈剂量效应。**结论** Tan 可减轻卵巢去势大鼠关节软骨退变, 其作用可能与其调节 TGF- β 1/Smad2/MMPs 信号通路有关。

【关键词】 丹参酮 II A 关节软骨 卵巢切除 大鼠

Tanshinone II A Ameliorates Cartilage Degeneration in Ovariectomized Rats by Regulating TGF- β 1/Smad2/MMPs Signaling Pathway GUO Qin, GUO Yuanli, LIAO Feng'er, TAO Ying[△]. Department of Obstetrics and Gynecology, The First Affiliated Hospital/The First Clinical Medicine School of Guangdong Pharmaceutical University, Guangzhou 510080, China

[△] Corresponding author, E-mail: 1140832540@qq.com

【Abstract】Objective To investigate the ameliorative effect of tanshinone II A (Tan) on osteoarticular degeneration in ovariectomized rats (a postmenopausal estrogen deficiency model) and the mechanisms involved. **Methods** Eight-week-old female Sprague Dawley (SD) rats were randomly allocated to 5 groups ($n=10$ each), including a Sham operation group (Sham), an ovariectomy group (OVX), and low, medium, and high-dose Tan groups. Eight weeks after bilateral ovariectomy, the rats in the low, medium, and high-dose Tan groups were treated with Tan at the doses of 5, 10, and 20 mg/kg for a duration of 28 days. Evaluation of the rat articular cartilage was performed using X-ray imaging, anatomical observation, hematoxylin and eosin (H&E) staining, and toluidine blue staining. Immunohistochemistry was performed to assess the expression levels of transforming growth factor β 1 (TGF- β 1), phosphorylated-smad2 (p-Smad2), type II collagen (C II), matrix metalloproteinase 9 (MMP-9), and MMP-13 in the cartilage tissue. **Results** The knee joints of the OVX rats exhibited narrowed joint spaces, osteophyte formation, cartilage erosion or even localized cartilage cracks, faded methylene blue staining on the cartilage surface, disordered arrangement of chondrocytes, unclear or interrupted tidal line, and increased Kellgren-Lawrence grading, Pelletier grading, Mankin grading, and OARSI scores compared to those of the Sham group ($P < 0.01$), as revealed by X-ray imaging, anatomical observation, and histological examination results. Tan ameliorated the degenerative changes in the knee joint caused by OVX in a dose-dependent manner while improving Kellgren-Lawrence grading, Pelletier grading, Mankin grading, and OARSI scores. Immunohistochemistry findings showed that TGF- β 1, p-Smad2, and C II expression levels were significantly increased ($P < 0.01$), while MMP-9 and MMP-13 expression levels were significantly decreased ($P < 0.01$) in the articular cartilage of the Tan group compared to those of the OVX group, with all these effects being dose-dependent. **Conclusion** Tan mitigates articular cartilage degeneration in ovariectomized rats, which may be related to the regulation of TGF- β 1/Smad2/MMPs signaling pathway.

【Key words】 Tanshinone II A Articular cartilage Ovariectomy Rat

* 广东省医学科学技术研究基金项目 (No. A2019364) 资助

[△] 通信作者, E-mail: 1140832540@qq.com

出版日期: 2024-07-20

关节软骨退行性变是绝经后妇女的常见病,以关节疼痛和活动障碍为主要的临床特征,严重影响患者的生活质量^[1]。由于雌激素缺乏导致的关节软骨退行性变的具体发病机制尚不清楚,因此临床上多以补充雌激素类药物来减缓疾病进展,口服非甾体抗炎药、止痛药以及关节腔注射润滑剂等保守治疗手段来改善症状^[2-3]。但长期服用雌激素类药物可能会导致月经不调、肥胖和性欲改变,甚至会增加妇科肿瘤和心血管疾病的患病风险^[2,4]。另外,对症治疗药物也不能控制该病的进展^[3]。因此,探索新的有效的治疗该病的药物尤为重要。

丹参酮II A(tanshinone II A, Tan)是从唇形科植物丹参的干燥根和根茎中提取的能发挥药理作用的主要活性化合物^[5-6]。近来研究发现, Tan能缓解骨关节炎模型大鼠的软骨退变并能抑制炎症反应^[7]。另有报道显示, Tan能改善卵巢切除(ovariectomy, OVX)大鼠的骨质疏松^[8]。目前, Tan对雌激素缺乏导致的软骨退行性变的作用并不清楚。OVX大鼠模型显示骨量减少、骨组织破坏和关节软骨退变^[8-9],其病理表现和疾病进展与人绝经后雌激素缺乏导致的骨退行性病变相似,因此本研究采用此模型观察Tan是否能改善OVX大鼠关节软骨退行性变,并分析潜在的机制,以期Tan用于雌激素缺乏导致的关节软骨退行性变的治疗提供理论基础。

1 材料与方法

1.1 主要药物与试剂

Tan(纯度:HPLC \geq 98%,上海源叶生物科技有限公司);转化生长因子 β 1(transforming growth factor β 1, TGF- β 1)、II型胶原(type II collagen, CII)水平,基质金属蛋白酶9(matrix metalloproteinase 9, MMP-9)、基质金属蛋白酶13(matrix metalloproteinase 13, MMP-13)和磷酸化的Smad2(p-Smad2)抗体(美国Santa Cruz公司);免疫组化EnVision二步染色试剂盒(美国DAKO公司)。

1.2 实验动物

8周龄(体质量220~250 g)雌性SD大鼠50只购于广州锐格生物科技有限公司(SCXK(粤)2023-0059),饲养于温度22℃、12 h光照/12 h黑暗的屏蔽环境,允许自由饮水及摄食。实验方案符合医学实验动物伦理委员会要求,并获得伦理委员会批准,批准号2022-083。

1.3 分组、造模与给药处理

适应性饲养5 d后,将大鼠随机分为5组(每组10只):假手术组(Sham)、卵巢切除组(OVX)、低剂量Tan组(L-Tan)、中剂量Tan组(M-Tan)和高剂量Tan组(H-Tan)。按文献^[8-10]方法进行双侧卵巢切除造模。造模方法简述:

以1%戊巴比妥钠(50 mg/kg)经腹腔注射麻醉后,背部下方横行切口,剪除长毛,切开皮肤1 cm,分别在脊柱两侧切开背肌1 cm,切口视野中可见一乳白色脂肪团,用小镊子将脂肪团拉出切口外,分离脂肪团,见到粉红色卵巢,摘除卵巢,同法摘除另一侧的卵巢,缝合伤口,术后进行3 d的青霉素注射防止感染。Sham组大鼠仅去除卵巢周围少量脂肪组织。双侧卵巢切除术后8周后, L-Tan、M-Tan和H-Tan组每只大鼠分别灌胃5、10和20 mg/kg Tan(与分组方法对应, Tan剂量参考^[7-8,11]),每日1次,连续给药28 d。Sham和OVX组大鼠仅灌胃同体积生理盐水。在最后一次给药(第28天)后24 h,安乐死并采集膝关节软骨进行测定分析。

1.4 X射线检查

在安乐死前,对各组大鼠的膝盖进行X射线检查。将右膝位于中外侧位置,使用便携式X射线装置拍摄膝关节的数字图像,操作电压为220 V,峰值为45 V,曝光时间为0.32 s^[12]。由两名对本研究不知情的放射科技师阅片,并按照文献^[13]方法,以Kellgren-Lawrence分级对其进行评分,评分越高则越严重。当评分不一致时,通过讨论确定评分结果。Kellgren-Lawrence分级标准:0,正常;1,可疑关节间隙狭窄;2,小骨赘,关节间隙可疑狭窄;3,中等骨赘,关节间隙狭窄;4,大量骨赘,严重关节间隙狭窄,软骨下骨硬化。

1.5 解剖学观察

X射线检查后,解剖大鼠膝关节,用数码相机拍摄大鼠膝盖的滑车、髌骨和胫骨平台。按文献^[14]方法,以Pelletier分级评分系统对肉眼软骨病变评分,评分越高则越严重。Pelletier分级评分系统的评分标准:0,外观正常;1,软骨表面轻微的黄化;2,有小面积的软骨侵蚀;3,大面积侵蚀延伸至软骨下骨;4,软骨下骨外露。

1.6 组织学检测

大鼠膝关节组织脱钙后,用体积分数4%多聚甲醛固定后用石蜡包埋,并切成5 μ m厚的切片。将石蜡切片干燥45 min,然后脱蜡至水。分别进行常规苏木精和伊红(HE)染色和甲苯胺蓝(TB)染色,用Olympus BX51光学显微镜观察载玻片并拍照。由两名对本研究不知情的病理技师阅片,并按照文献^[7,15-16]方法,根据Mankin评分系统和国际骨关节炎研究协会(OARSI)评分系统对关节结构、软骨破坏和骨侵蚀的组织学进行评分,评分越高则越严重。当评分不一致时候,通过讨论确定评分结果。

1.7 免疫组化法检测

将脱蜡至水的切片用0.3%的过氧化氢阻断内源性过氧化物活性和高温高压修复处理后,用正常山羊血清孵

育切片以减少非特异性结合,然后用抗TGF- β 1、p-Smad2、C II、MMP-9、MMP-13抗体(均1:200)在4℃下孵育过夜。免疫组化EnVision二步染色法参照试剂盒说明书进行。以PBS代替一抗作为阴性对照。用Olympus BX51光学显微镜观察并拍照,每只大鼠至少选取5个不连续切片,每个切片任选5个随机视野,用Image J软件量化每个视野中阳性染色光密度值。

1.8 统计学方法

本实验数据均采用 $\bar{x} \pm s$ 表示,并利用Graphpad Prism 9.0软件进行后续统计学分析。多组定量资料的比较采用单因素方差分析法,组间均数的两两比较采用LSD-*t*法。 $P < 0.05$ 为差异有统计学意义。

2 结果

2.1 X射线照相检查

X射线检查(图1)显示,Sham组大鼠膝关节的关节面光滑(a箭头显示)、关节间隙正常;OVX组大鼠膝关节的关节间隙狭窄、骨赘形成(b箭头显示)以及骨质流失;L-Tan、M-Tan和H-Tan组病变明显减轻,其中H-Tan组膝关节已趋向Sham组。对其进行Kellgren-Lawrence分级评分,与Sham组比较,OVX组评分增高($P < 0.01$);与OVX组比较,Tan组Kellgren-Lawrence分级评分随Tan剂量依赖性递减。

2.2 软骨损伤的解剖学宏观观察

图2A显示,Sham组大鼠膝关节软骨(滑车、髌骨和胫骨平台)表面光滑(虚线箭头显示),无软骨糜烂;OVX组大鼠膝关节软骨滑车表面欠光滑可见明显软骨侵蚀(实线箭头显示),髌骨和胫骨平台软骨表面可见溃疡面(实线箭头显示),侵蚀达软骨深层;L-Tan、M-Tan和H-Tan组大鼠膝关节软骨的损伤较OVX组均明显减轻,其中H-Tan组膝关节软骨外观已趋向Sham组。对关节进行Pelletier分级评分,结果(图2B)显示,与Sham组比较,OVX组滑车、髌骨和胫骨平台的Pelletier分级评分均增高($P < 0.01$);与OVX组比较,Tan组Pelletier分级评分随Tan剂量依赖性递减。

2.3 软骨组织学评价

HE染色(图3A,上)显示,Sham组软骨表面光滑(虚线箭头显示)、软骨细胞排列整齐;OVX组可见软骨侵蚀、软骨细胞排列紊乱、炎性细胞浸润和裂隙(实线箭头显示);L-Tan、M-Tan和H-Tan组大鼠膝关节软骨表面趋向光滑,其中H-Tan组膝关节软骨外观已趋向Sham组。TB染色(图3A,下)显示,Sham组软骨表面光滑,软骨细胞排列规整,着色均匀,潮线完整、结构清晰(虚线箭头显示);OVX组可见软骨侵蚀和裂隙(实线箭头显示),软骨细胞排列紊乱,着色浅(***)甚至消失,潮线不清甚至中断;L-Tan、M-Tan和H-Tan组大鼠膝关节软骨表面趋向

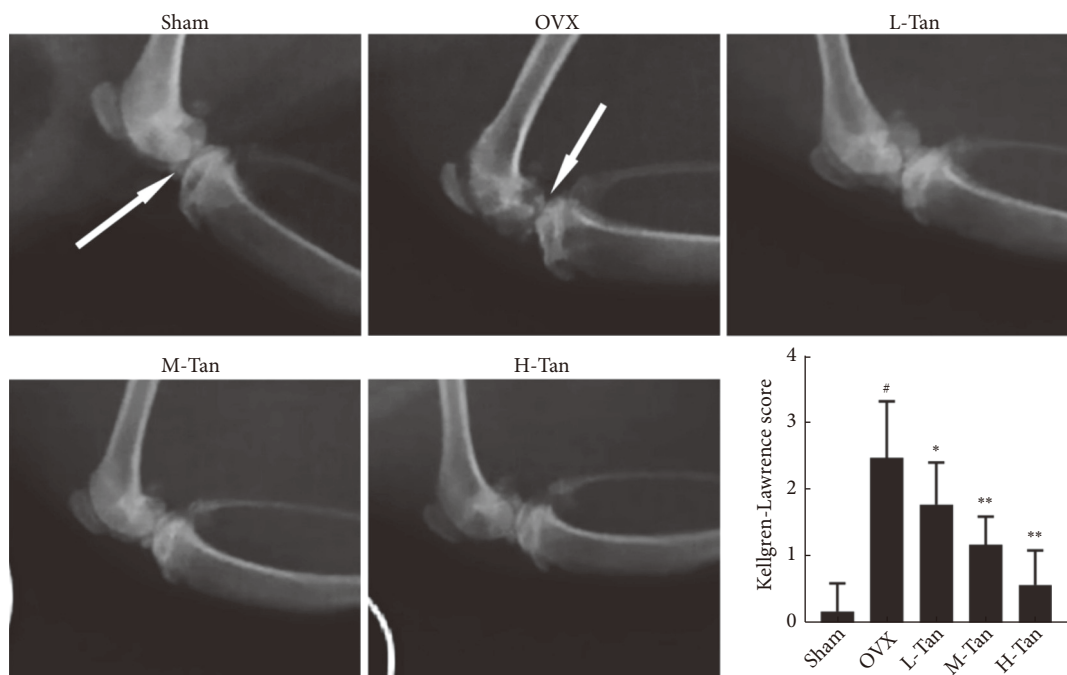


图1 大鼠膝关节X射线图和Kellgren-Lawrence分级评分

Fig 1 Representative X-ray images of knee joints and Kellgren-Lawrence grading scale scores in different groups of rats

Arrow a indicates smooth articular surface; arrow b indicates osteophyte formation. L-Tan: 5 mg/kg Tan; M-Tan: 10 mg/kg Tan; H-Tan: 20 mg/kg Tan. $n=10$. [#] $P < 0.01$, vs. Sham group; ^{*} $P < 0.05$, ^{**} $P < 0.01$, vs. OVX group.

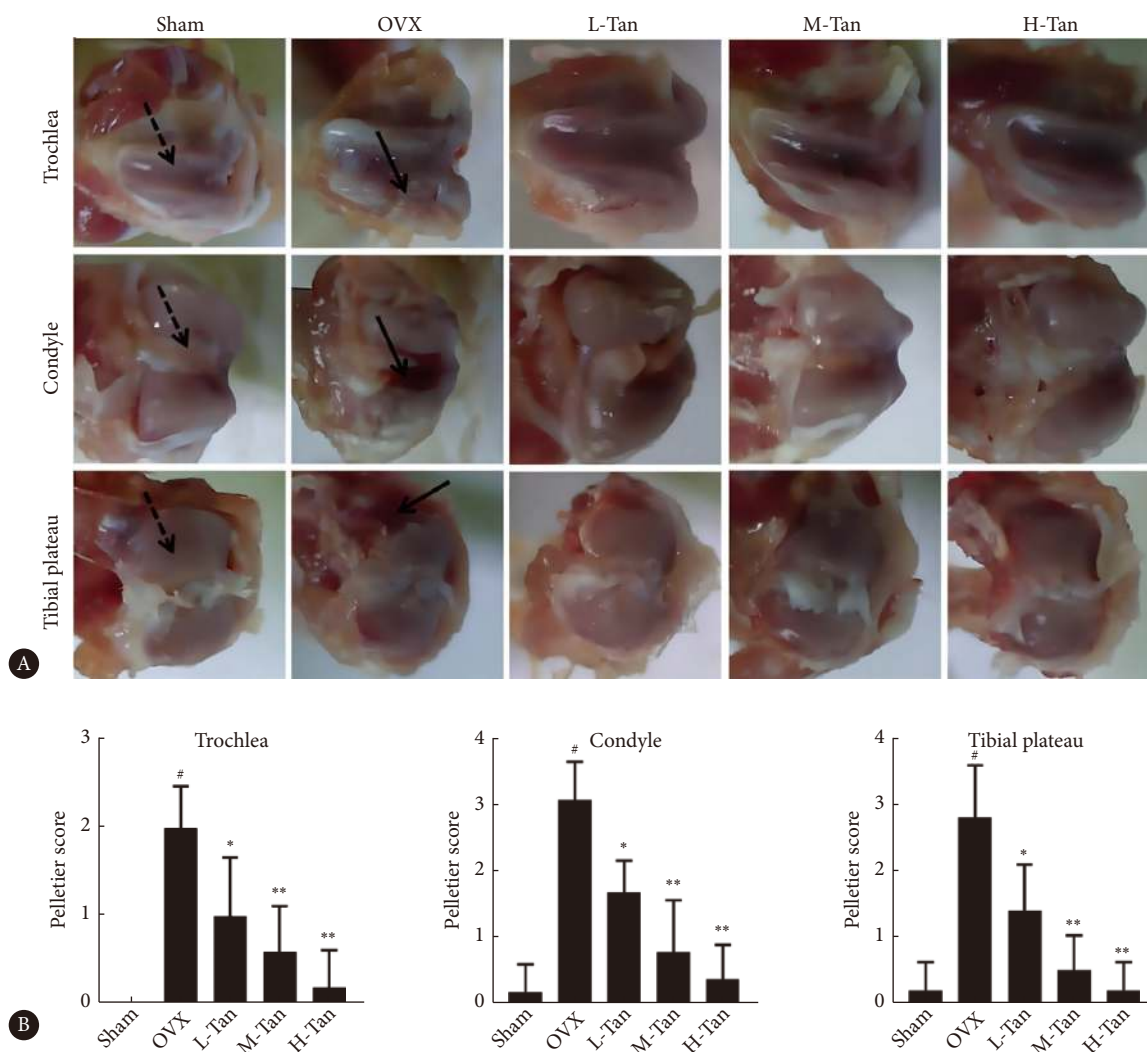


图2 各组右膝关节软骨表面(滑车、髁和胫骨平台)图像(A)及其Pelletier分级评分(B)

Fig 2 Images of the surface of the right knee cartilage (including trochlea, condyle, and tibial plateau) (A) and Pelletier grading scores (B) in each group

The dashed arrow indicates smooth cartilage surface; the solid arrow indicates cartilage erosion. L-Tan, M-Tan, and H-Tan denote the same as those in Fig 1. $n=10$. # $P<0.01$, vs. Sham group; * $P<0.05$, ** $P<0.01$, vs. OVX group.

光滑, 软骨表面着色逐渐加深, 其中H-Tan组膝关节软骨外观已趋向Sham组。对HE染色和TB染色的组织切片进行Mankin评分和OARSI评分, 结果(图3B、3C)显示, 与Sham组比较, OVX组Mankin评分和OARSI评分均增高($P<0.01$); 与OVX组比较, Tan组的Mankin评分和OARSI评分均随Tan剂量依赖性递减。

2.4 各组软骨组织中TGF- β 1、p-Smad2、C II、MMP-9和MMP-13表达情况

免疫组化结果(图4)显示, 与Sham组比较, OVX组大鼠软骨组织中TGF- β 1、p-Smad2和C II表达降低($P<0.01$), MMP-9和MMP-13表达增加($P<0.01$); 与OVX组比较, L-Tan组大鼠软骨组织中TGF- β 和C II表达未见明显变化, p-Smad2表达增加($P<0.01$), MMP-9和

MMP-13表达降低($P<0.01$), M-Tan和H-Tan组大鼠软骨组织中TGF- β 1、p-Smad2和C II表达均增加($P<0.01$), MMP-9和MMP-13表达均降低($P<0.01$)。

3 讨论

关节退行性变在绝经后女性中较为常见, 且其发生率随着年龄增长而逐渐上升^[1]。然而, 目前尚无根治该病的方法。因此, 探索治疗该疾病的药物显得尤为重要。虽然关节退行性变的具体发病机制并不完全清楚, 但关节软骨损伤、退化和骨质疏松是其主要的病理改变^[10, 17-18]。OVX模型与人绝经后雌激素缺乏的生理学类似, 前期已有研究以OVX大鼠模型证明了Tan有类似雌激素样活性, 能改善OVX大鼠的卵巢形态和骨形态并提高骨密度和骨

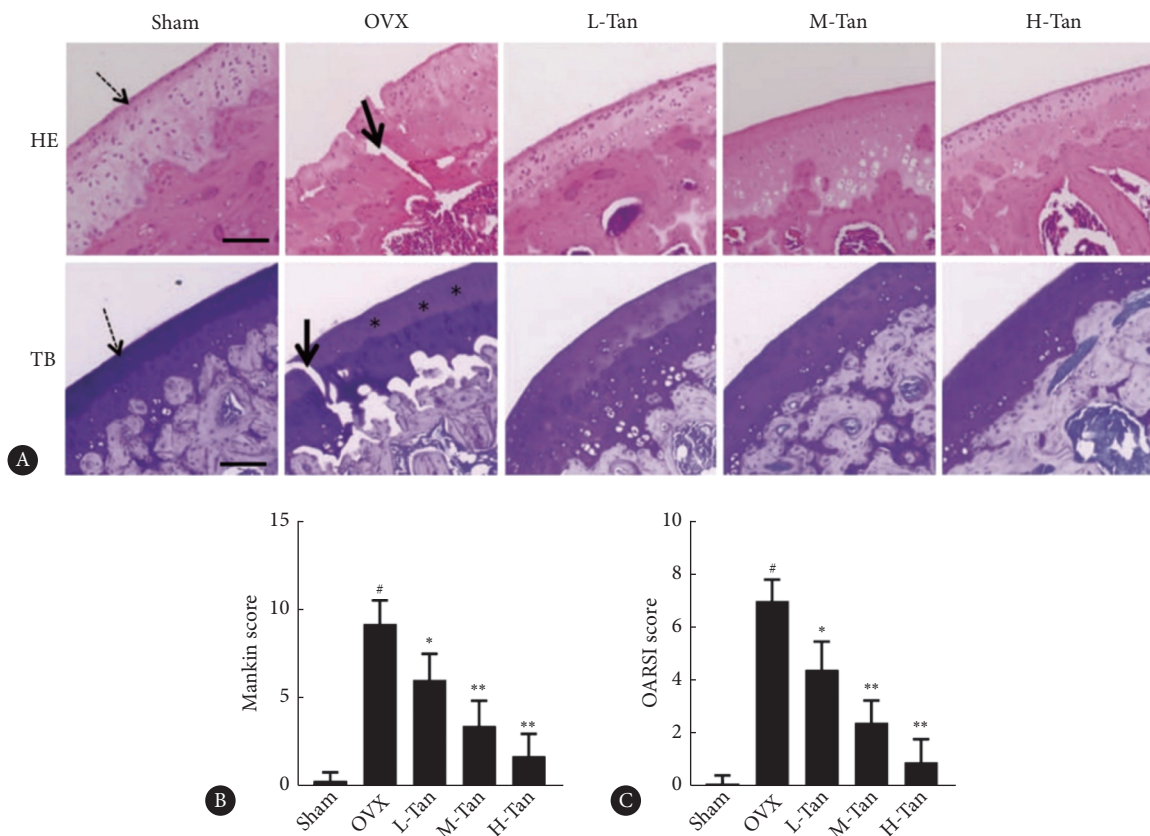


图 3 各组大鼠膝关节软骨代表性HE和TB染色图像 (A) 及Mankin评分 (B) 和OARSI评分 (C)

Fig 3 Representative HE and TB staining images of knee cartilage, Mankin scores (B) and OARSI scores (C) of the rats in each group

A, scale bar=200 μm . The dashed arrow indicates smooth cartilage surfaces; the solid arrow indicates cartilage fissure. *** indicates light coloring. L-Tan, M-Tan, and H-Tan denote the same as those in Fig 1. $n=10$. [#] $P<0.01$, vs. Sham group; ^{*} $P<0.05$, ^{**} $P<0.01$, vs. OVX group.

应力^[8]。本研究进一步以OVX大鼠模型探讨Tan对关节软骨损伤和退化是否具有治疗作用。前期已有研究表明, Tan能缓解前交叉韧带切断术构建的骨关节炎模型大鼠的软骨退变并能抑制炎症反应^[7]。以上提示, Tan也可能对OVX大鼠的软骨退变具有改善作用, 这一假设也被本研究证实, Tan治疗能明显改善OVX大鼠的软骨侵蚀症状。综合前人^[8]研究结果, 本研究提示Tan可能是治疗绝经后女性关节退行性变的潜在药物。

本研究进一步探讨了Tan对OVX大鼠的软骨保护机制。已有的研究^[19-22]表明, TGF- β 1与关节退行性变关系密切。生理情况下, TGF- β 1可通过激活Smad2信号转导通路抑制软骨细胞的分化, 维持软骨细胞的正常表型, 同时促进软骨细胞合成细胞外基质, 使关节软骨具有最大限度地吸收、缓冲应力的生物力学特性^[20-22]。另外, TGF- β 1可通过Smad2信号促进软骨细胞下游基因的转录, 促进成细胞外基质相关蛋白C II和蛋白聚糖的表达增加, 同时抑制基质降解酶如MMP-9和MMP-13表达^[20-23]。已有研究^[13, 23-24]表明, 绝经后发生关节软骨退行性变的女性以及OVX动物模型的膝关节软骨中TGF- β 1和p-Smad2表达

受到抑制, 同时MMP-9和MMP-13表达上调。在OVX动物模型中, 进一步给予抑制TGF- β 1/Smads能增加软骨基质降解, 加重软骨侵蚀, 与此同时, 关节软骨也开始出现血管化和局灶性钙化^[25-26]。激活TGF- β 1/Smads能改善OVX动物模型的关节软骨退行性变的症状^[26-27]。本研究显示, 经Tan治疗的OVX大鼠软骨组织中TGF- β 1、p-Smad2和C II表达增加, 同时MMP-9和MMP-13表达降低, 说明Tan可能通过激活TGF- β 1/Smad2信号增加OVX大鼠软骨的软骨基质的合成同时抑制其降解。

综上所述, Tan对OVX大鼠的关节软骨具有保护作用, 其机制可能为其通过促进TGF- β 1/Smad2信号活性来刺激软骨基质合成, 并同时抑制其降解。另外, 本研究提示, Tan有潜力作为绝经后妇女关节软骨退行性变的候选治疗药物。然而, 本文重点关注软骨细胞, Tan是否对成骨细胞和破骨细胞具有类似的治疗效果尚不明确, 仍需进一步深入研究。

* * *

作者贡献声明 郭琴负责论文构思、数据审编、调查研究、研究方法、

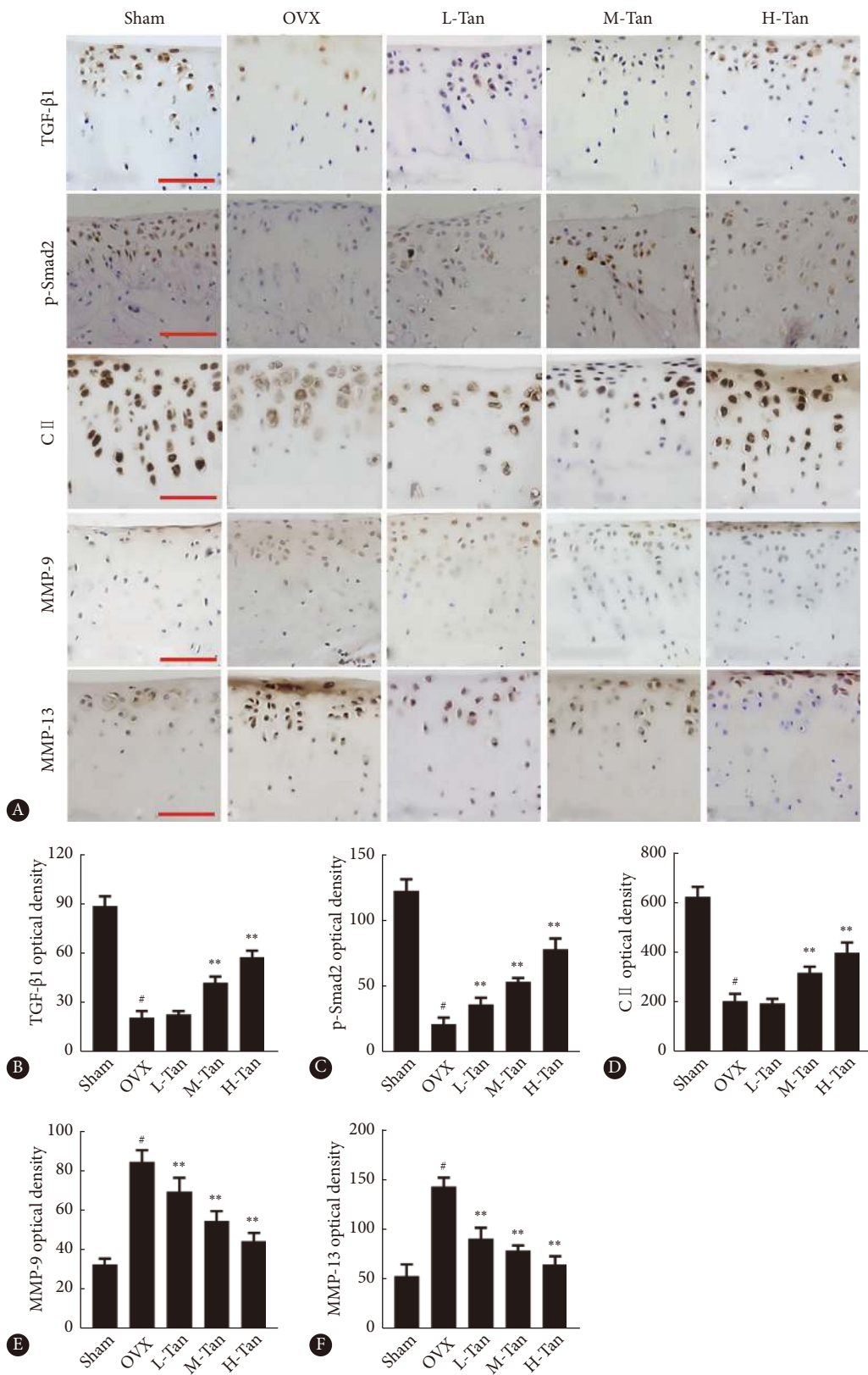


图 4 各组大鼠关节软骨中 TGF- β 1、p-Smad2、C II、MMP-9 和 MMP-13 的表达

Fig 4 Expression of TGF- β 1, p-Smad2, C II, MMP-9, and MMP-13 in the articular cartilage of rats in each group

A, Immunohistochemical images of TGF- β 1, p-Smad2, C II, MMP-9, and MMP-13 expression in the knee joint (scale bar=100 μ m); B-F, quantitative results of TGF- β 1 (B), p-Smad2 (C), C II (D), MMP-9 (E), and MMP-13 (F) expression. L-Tan, M-Tan, and H-Tan denote the same as those in Fig 1. $n=10$. [#] $P<0.01$, vs. Sham group; ^{*} $P<0.05$, ^{**} $P<0.01$, vs. OVX group.

验证、初稿写作和审读与编辑写作,郭苑莉负责正式分析和调查研究,廖凤儿负责调查研究,陶莹负责监督指导。所有作者已经同意将文章提交给本刊,且对将要发表版本进行最终定稿,并同意对工作的所有方面负责。

Author Contribution GUO Qin is responsible for conceptualization, data curation, investigation, methodology, validation, writing--original draft, and writing--review and editing. GUO Yuanli is responsible for formal analysis and investigation. LIAO Feng'er is responsible for investigation. TAO Ying is responsible for supervision. All authors consented to the submission of the article to the Journal. All authors approved the final version to be published and agreed to takeresponsibility for all aspects of the work

利益冲突 所有作者均声明不存在利益冲突

Declaration of Conflicting Interests All authors declare no competing interests.

参 考 文 献

- [1] OKADA S, TANIGUCHI M, YAGI M, *et al.* Ultrasonographic echo intensity in the medial femoral cartilage is enhanced prior to cartilage thinning in women with early mild knee osteoarthritis. *Knee Surg Sports Traumatol Arthrosc*, 2023, 31(9): 3964–3970. doi: [10.1007/s00167-023-07440-w](https://doi.org/10.1007/s00167-023-07440-w).
- [2] BROWN J P. Long-term treatment of postmenopausal osteoporosis. *Endocrinol Metab (Seoul)*, 2021, 36(3): 544–552. doi: [10.3803/EnM.2021.301](https://doi.org/10.3803/EnM.2021.301).
- [3] PAN M, PAN X, ZHOU J, *et al.* Update on hormone therapy for the management of postmenopausal women. *Biosci Trends*, 2022, 16(1): 46–57. doi: [10.5582/bst.2021.01418](https://doi.org/10.5582/bst.2021.01418).
- [4] POLYZOS S A, ANASTASILAKIS A D, EFSTATHIADOU Z A, *et al.* Postmenopausal osteoporosis coexisting with other metabolic diseases: treatment considerations. *Maturitas*, 2021, 147: 19–25. doi: [10.1016/j.maturitas.2021.02.007](https://doi.org/10.1016/j.maturitas.2021.02.007).
- [5] 任陈, 李璐, 徐艳侠, 等. 丹参酮 II A 通过 Nrf2 调节 ALDOC 减轻海马神经元放射性损伤的机制. *实用医学杂志*, 2019, 35(9): 2040–2044. doi: [10.3969/j.issn.1006-5725.2019.13.003](https://doi.org/10.3969/j.issn.1006-5725.2019.13.003).
REN C, LI L, XU Y X, *et al.* Tanshinone II A regulates ALDOC to alleviate radiation injury in hippocampal neurons. *J Prac Med*, 2019, 35(9): 2040–2044. doi: [10.3969/j.issn.1006-5725.2019.13.003](https://doi.org/10.3969/j.issn.1006-5725.2019.13.003).
- [6] SI J C, LIU B B, QI K R, *et al.* Tanshinone IIA inhibited intermittent hypoxia induced neuronal injury through promoting autophagy via AMPK-mTOR signaling pathway *J Ethnopharmacol*, 2023, 315: 116677. doi: [10.1016/j.jep.2023.116677](https://doi.org/10.1016/j.jep.2023.116677).
- [7] 张金锋, 徐志龙, 吴梦, 等. 丹参酮 II A 通过抑制信号通路延缓膝骨关节炎大鼠软骨退变及抑制局部炎症的研究. *中国药理学杂志*, 2021, 56(23): 1918–1926. doi: [10.11669/cpj.2021.23.008](https://doi.org/10.11669/cpj.2021.23.008).
ZHANG J F, XU Z L, WU M, *et al.* Tanshinone II A alleviates cartilage degeneration and local inflammation in rats with knee osteoarthritis by inhibiting pathway. *Chin Pharm J*, 2021, 56(23): 1918–1926. doi: [10.11669/cpj.2021.23.008](https://doi.org/10.11669/cpj.2021.23.008).
- [8] 杨芳芳, 慧慧荣, 高玉海. 丹参酮 II A 对去卵巢大鼠骨密度及骨形态计量学的影响. *中华骨质疏松和骨矿盐疾病杂志*, 2018, 11(2): 166–171. doi: [10.3969/j.issn.1674-2591.2018.02.011](https://doi.org/10.3969/j.issn.1674-2591.2018.02.011).
YANG F F, XI H R, GAO Y H. Effect of tanshinone II A on bone mineral density and bone histomorphometry in ovariectomized rat. *Chin J Osteoporos Bone Miner Res*, 2018, 11(2): 166–171. doi: [10.3969/j.issn.1674-2591.2018.02.011](https://doi.org/10.3969/j.issn.1674-2591.2018.02.011).
- [9] WADA H, ASO K, IZUMI M, *et al.* The effect of postmenopausal osteoporosis on subchondral bone pathology in a rat model of knee osteoarthritis. *Sci Rep*, 2023, 13(1): 2926. doi: [10.1038/s41598-023-29802-7](https://doi.org/10.1038/s41598-023-29802-7).
- [10] PING S H, TIAN F M, ZHAO Z M, *et al.* Protective effects of equol on the cartilage and subchondral bone in ovariectomized rats with osteoarthritis. *Iran J Basic Med Sci*, 2022, 25(10): 1228–1233. doi: [10.22038/IJBMS.2022.59036.13115](https://doi.org/10.22038/IJBMS.2022.59036.13115).
- [11] LI H L, LI T, CHEN Z Q, *et al.* Tanshinone IIA reduces pyroptosis in rats with coronary microembolization by inhibiting the TLR4/MyD88/NF-κB/NLRP3 pathway. *Korean J Physiol Pharmacol*, 2022, 26(5): 335–345. doi: [10.4196/kjpp.2022.26.5.335](https://doi.org/10.4196/kjpp.2022.26.5.335).
- [12] CHE AHMAD TANTOWI N A, HUSSIN P, LAU S F, *et al.* Mistletoe fig (*Ficus deltoidea* Jack) leaf extract prevented postmenopausal osteoarthritis by attenuating inflammation and cartilage degradation in rat model. *Menopause*, 2017, 24(9): 1071–1080. doi: [10.1097/GME.0000000000000882](https://doi.org/10.1097/GME.0000000000000882).
- [13] 张陆, 刘志昂, 姜岩, 等. iPSC-MSCs 与 hUC-MSCs 治疗大鼠膝关节炎的实验研究. *中国骨质疏松杂志*, 2021, 27(6): 798–802. doi: [10.3969/j.issn.1006-7108.2021.06.004](https://doi.org/10.3969/j.issn.1006-7108.2021.06.004).
ZHANG L, LIU Z A, JIANG Y, *et al.* Experimental study of iPSC-MSCs and hUC-MSCs in the treatment of knee osteoarthritis in rats. *Chin J Osteoporos*, 2021, 27(6): 798–802. doi: [10.3969/j.issn.1006-7108.2021.06.004](https://doi.org/10.3969/j.issn.1006-7108.2021.06.004).
- [14] BEI M J, TIAN F M, XIAO Y P, *et al.* Raloxifene retards cartilage degradation and improves subchondral bone micro-architecture in ovariectomized rats with patella baja-induced - patellofemoral joint osteoarthritis. *Osteoarthritis Cartilage*, 2020, 28(3): 344–355. doi: [10.1016/j.joca.2019.06.014](https://doi.org/10.1016/j.joca.2019.06.014).
- [15] PING S H, TIAN F M, LIU H, *et al.* Raloxifene inhibits the overexpression of TGF-β1 in cartilage and regulates the metabolism of subchondral bone in rats with osteoporotic osteoarthritis. *Bosn J Basic Med Sci*, 2021, 21(3): 284–293. doi: [10.17305/bjbm.2020.5142](https://doi.org/10.17305/bjbm.2020.5142).
- [16] GUI T, WEI Y, LUO L, *et al.* Activating EGFR signaling attenuates osteoarthritis development following loading injury in mice. *J Bone Miner Res*, 2022, 37(12): 2498–2511. doi: [10.1002/jbmr.4717](https://doi.org/10.1002/jbmr.4717).
- [17] KUBO N, AWADA T, HIROSE N, *et al.* Longitudinal effects of estrogen on mandibular growth and changes in cartilage during the growth period in rats. *Dev Biol*, 2022, 492: 126–132. doi: [10.1016/j.ydbio.2022.10.007](https://doi.org/10.1016/j.ydbio.2022.10.007).
- [18] HAURU R, RIEPPO L, TUOMISTO T, *et al.* Fourier-transform infrared study on effects of ageing, oestrogen level and altered dietary loading on rat mandibular condylar cartilage. *Orthod Craniofac Res*, 2024, 27(1): 151–164. doi: [10.1111/ocr.12693](https://doi.org/10.1111/ocr.12693).

- [19] LI S, NIU G, WU Y, *et al.* Vitamin D prevents articular cartilage erosion by regulating collagen II turnover through TGF- β 1 in ovariectomized rats. *Osteoarthritis Cartilage*, 2016, 24(2): 345–353. doi: 10.1016/j.joca.2015.08.013.
- [20] KIM J G, RIM Y A, JU J H. The role of transforming growth factor beta in joint homeostasis and cartilage regeneration. *Tissue Eng Part C Methods*, 2022, 28(10): 570–587. doi: 10.1089/ten.TEC.2022.0016.
- [21] HUNZIKER E B, SHINTANI N, LIPPUNER K, *et al.* In major joint diseases the human synovium retains its potential to form repair cartilage. *Sci Rep*, 2023, 13(1): 10375. doi: 10.1038/s41598-023-34841-1.
- [22] LIU L, ZHAO C, ZHANG H, *et al.* Asporin regulated by miR-26b-5p mediates chondrocyte senescence and exacerbates osteoarthritis progression via TGF- β 1/Smad2 pathway. *Rheumatology (Oxford)*, 2022, 61(6): 2631–2643. doi: 10.1093/rheumatology/keab725.
- [23] CHE X, JIN X, PARK N R, *et al.* Cbf β is a novel modulator against osteoarthritis by maintaining articular cartilage homeostasis through TGF- β signaling. *Cells*, 2023, 12(7): 1064. doi: 10.3390/cells12071064.
- [24] MA X, CAI D, ZHU Y, *et al.* L-glutamine alleviates osteoarthritis by regulating lncRNA-NKILA expression through the TGF- β 1/SMAD2/3 signalling pathway. *Clin Sci (Lond)*, 2022, 136(13): 1053–1069. doi: 10.1042/CS20220082.
- [25] HUANG W R, TU J X, QIAO A Q, *et al.* GW842166X alleviates osteoarthritis by repressing LPS-mediated chondrocyte catabolism in mice. *Curr Med Sci*, 2022, 42(5): 1046–1054. doi: 10.1007/s11596-022-2627-z.
- [26] LIN X S, WANG H Y, ZHANG Z, *et al.* Effects of acupoint application therapy with TianGui powder on osteoporosis in ovariectomized rats through TGF- β 1 and Smad2/3 signaling pathway. *Orthop Surg*, 2019, 11(1): 143–150. doi: 10.1111/os.12427.
- [27] CHEN Y, LI X, TANG X, *et al.* Combined extracts of herba epimedii and fructus ligustri lucidi rebalance bone remodeling in ovariectomized rats. *Evid Based Complement Alternat Med*, 2019, 2019: 1596951. doi: 10.1155/2019/1596951.

(2024-02-24收稿, 2024-05-06修回)

编辑 吕熙



开放获取 本文使用遵循知识共享署名—非商业性使用4.0国际许可协议(CC BY-NC 4.0), 详细信息请访问

<https://creativecommons.org/licenses/by/4.0/>。

OPEN ACCESS This article is licensed for use under Creative Commons Attribution-NonCommercial 4.0 International license (CC BY-NC 4.0). For more information, visit <https://creativecommons.org/licenses/by/4.0/>.

© 2024 《四川大学学报(医学版)》编辑部 版权所有

Editorial Office of *Journal of Sichuan University (Medical Science)*